

OPHTHALMOLOGIC EXAMINATION

Date 2/1/07

*Thompson Brown*

OD

OS

CULTURE

VISION

menace

maze

tracking

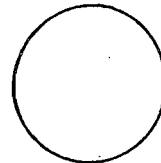
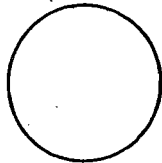
GLOBE

size

position

motility

PUPIL



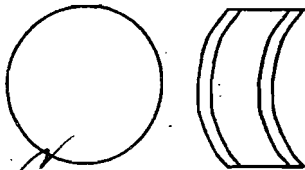
size

shape

direct PLR

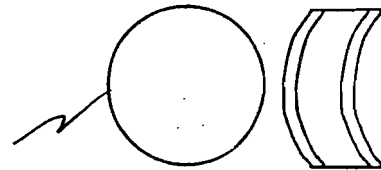
consensual PLR

CORNEA



mm/min

STT



mm/min

fluorescein stain

IOP

at

gms =

mm Hg

schiotz

at

gms =

mm Hg

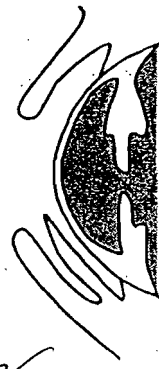
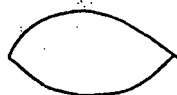
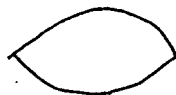mm Hg

applanation

mm Hg

MYDRIATIC DROP TIME

EYELIDS



3rd EYELID

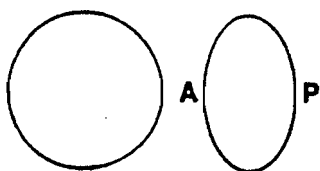
CONJUNCTIVA

ANTERIOR CHAMBER

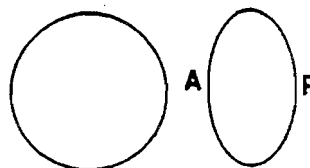
OD

OS

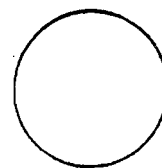
IRIS



LENS



FUNDUS



OTHER

**SPECIAL PROCEDURES**

N-L flush \_\_\_\_\_  
 Cytology \_\_\_\_\_  
 Gonioscopy \_\_\_\_\_  
 Other \_\_\_\_\_

**DIAGNOSIS** \_\_\_\_\_

*OD - N*

**RECOMMENDED TREATMENT AND CLIENT EDUCATION**

1. *OK to wear*

\_\_\_\_\_

\_\_\_\_\_

\_\_\_\_\_

\_\_\_\_\_

Signature \_\_\_\_\_  
Student

Signature \_\_\_\_\_  
Clinician